

EFFICACY OF HEMIARTHROPLASTY FOR HUMERAL FOUR-PART FRACTURES IN ELDERLY

¹Dr. Satish Bobade, ²Dr. Sandesh Bobade, ³Dr. Pravin Deokate

¹Assistant Professor, Government Medical College, Baramati

²Senior Resident, Government medical College, Baramati

³Associate Professor, BJ Medical College, Pune

Article Info: Received 16 May 2020; Accepted 10 July 2020

DOI: <https://doi.org/10.32553/ijmbs.v4i7.1319>

Corresponding author: Dr. Satish Bobade

Conflict of interest: No conflict of interest.

Abstract

Background: There are four anatomic parts of the proximal humerus namely, head, greater tuberosity, lesser tuberosity, and surgical neck. 140° is the approx angle that is formed by the neck-shaft of the humeral. With prevalence rate of 5-6% among the elderly its incidence increase with the advancement in the age. There are various factors affecting this advancement of the elderly patients towards the proximal humerus including increasing age, osteoporosis, age, sex and other similar factors.

Aim: To study the efficacy of Hemiarthroplasty for Humeral Four-part Fractures in Elderly Patients

Methods: It was an observational study. 30 patients were taken up for the study, who were diagnosed with humeral fracture. All the patients were included in the study after getting written consent from them. Radiography was done for all the patients from an AP view, a lateral shoulder view in the scapular plane, and of the axilla according to the Neer's classification.

Results: The above table shows that the number of patients was 10 and that of the female patients was 20. The mean age for the patients was 75.45±10.69 years. The VAS score before treatment was found to be ranged from 50-90 and the VAS score after treatment was found to be ranged from 75-95. The above table shows that the VAS pain was 20 in 3 months follow up time that increased to 25 in 1 year follow up time. The VAS disability score within 3 months follow up was 53 that reduced to 47 in 1 year follow-up period. The CMS activity score was in 3 months follow-up was 10.5 and that in 1 year follow up was 15. The CMS mobility after 3 months follow-up was 13 that increased to 22 in 1 year follow-up period.

Conclusion: In the light of above results and discussion it is evident that the Hemiarthroplasty is a more viable option for reducing pain and increasing mobility in elderly patients suffering from four-part humeral fracture as compared to any other operative technique.

Introduction

There are four anatomic parts of the proximal humerus namely, head, greater tuberosity, lesser tuberosity, and surgical neck. 140° is the approx angle that is formed by the neck-shaft of the humeralⁱ. Historically, 30° of humeral head retroversion has been considered normalⁱⁱ. Fractures of the proximal humerus have been accounted to be the third most common type of fracture in elderly patients with hip and distal radius fracture preceding itⁱⁱⁱ.

With prevalence rate of 5-6% among the elderly its incidence increase with the advancement in the age. There are various factors affecting this advancement of the elderly patients towards the proximal humerus including increasing age, osteoporosis, age, sex and other similar factors^{iv}. The pattern of this fracture is dependent on the mechanism of the injury as well as the density of the bone.

For example, three and four part proximal humerus fractures are a result of the low energy trauma^v.

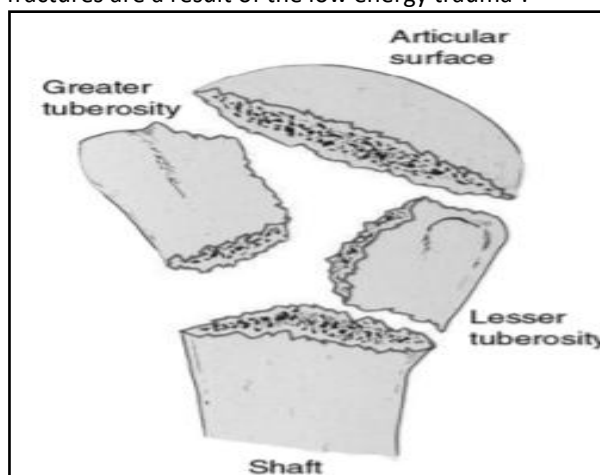


Figure 1: Codman classification of proximal^{vi}

There two different approaches for the treatment mechanism that include operative and non-operative methods^{vii}. On one hand, the non-operative mechanisms include a period of immobilization, such as an arm sling, followed by physiotherapy and exercise^{viii}. On the other hand the operative techniques include open reduction and internal fixation (ORIF), hemiarthroplasty (HA), reverse shoulder arthroplasty (RSA), intramedullary nailing (IN)^{ix}.

There has been a paucity of data regarding the best treatment mechanism or treating the proximal humerus fractures in the elderly patients. Therefore, the current study focused on analyzing the function, strength and pain score among the elderly patients treated with hemiarthroplasty in four-part humeral fracture.

Aim

To study the efficacy of Hemiarthroplasty for Humeral Four-part Fractures in Elderly Patients

Materials and methods

It was an observational study carried out in the orthopedic department out at our institute for a period of one year. 30 patients were taken up for the study, who were diagnosed with a humeral fracture. All the patients were included in the study after getting written consent from them. Radiography was done for all the patients from an AP view, a lateral shoulder view in the scapular plane, and of the axilla according to the Neer's classification. Patients with any existing mental disorders, suffering from additional trauma due to the humeral fracture and having open fractures were excluded from the study. The VAS score for all the patients was noted, and a follow-up was done for all the patients.

Results

Table 1:

Parameters	Values
Gender	
Male	10
Female	20
Age	75.45±10.69
VAS score range before treatment	50-90
VAS score after treatment	75-95

The above table shows that the number of patients was 10 and that of the female patients was 20. The mean age for the patients was 75.45±10.69 years. The VAS score before treatment was found to be ranged from 50-90 and the VAS score after treatment was found to be ranged from 75-95.

Table 2:

Variable	3 months follow up	1 year follow up
VAS Pain	20	25
VAS disability	53	47
Abductor strength (N)% contralateral shoulder	22	26
CMS	50	66
Total pain	13	15
Activity	10.5	15
Mobility	13	22
Strength	17	20

The above table shows that the VAS pain was 20 in 3 months follow up time that increased to 25 in 1 year follow up time. The VAS disability score within 3 months follow up was 53 that reduced to 47 in 1 year follow-up period. The Abductor strength (N)% contralateral shoulder was 22 in 3 months follow up that increased to 26 in 1 year follow up period.

The overall Constant-Murley Score (CMS) score was 50 in the 3 months follow-up time while it increased to 66 in 1 year follow up. The total CMS pain was 13 in 3 months follow-up and 15 in 1 year follow up. The CMS activity score was in 3 months follow-up was 10.5 and that in 1 year follow up was 15. The CMS mobility after 3 months follow-up was 13 that increased to 22 in 1 year follow-up period. The CMS strength for 3 month follow-up period was 17 that increased to 20 in 1 year follow-up period.

Discussion

It is evident that the accurate treatment mechanism for the humeral for part fracture in the elderly patients has been unclear as the percentage of four-part fracture is quite low. However, in the current study it was found that Hemiarthroplasty was found to be a better treatment for four-part fracture based on the VAS and CMS score. Similarly, Cadet et al., (2012)¹ found that the operative treatments were more apt as compared to non-operative treatment mechanisms. In the current study it was found that there was improvement in all the VAS scores as well as the CMS score in the 3 months and 1 year follow-up schedule the average VAS score in the current study was 50-90 before treatment and VAS score was 75-95 after treatment. Similar results were found in the study by Boons et al.,(2012)⁴ where the operative treatment mechanisms were found to have more improved VAS and CMS scores as compared to the non-operative techniques.

Conclusion

In the light of above results and discussion it is evident that the Hemiarthroplasty is a more viable option for reducing pain and increasing mobility in elderly patients suffering

from four-part humeral fracture as compared to any other operative technique. It minimizes the risk of implant failure, vascular necrosis and other complications. With improved VAS pain scores and CMS scores over longer follow-up period.

References

1. ⁱ Cadet ER, Ahmad CS. Hemiarthroplasty for Three- and Four-part Proximal Humerus Fractures. *Journal of the American Academy of Orthopaedic Surgeons*. 2012;20(1):17-26
2. ⁱⁱ Boileau P, Bicknell RT, Mazzoleni N, Walch G, Urien JP: CT scan method accurately assesses humeral head retroversion. *Clin Orthop Relat Res* 2008;466(3):661-669
3. ⁱⁱⁱ Chen L, Xing F, Xiang Z. Effectiveness and Safety of Interventions for Treating Adults with Displaced Proximal Humeral Fracture: A Network Meta-Analysis and Systematic Review. *Plos One*. 2016;11(11).
4. ^{iv} Boons HW, Goosen JH, Grinsven SV, Susante LV, Loon CJV. Hemiarthroplasty for Humeral Four-part Fractures for Patients 65 Years and Older. *Clin Orthop Relat Res*. 2012;470:3483-491.
5. ^v Price D, Bush F, Long S, Harkins SW. A comparison of pain measurement characteristics of mechanical visual analogue and simple numerical rating scales. *Pain*. 1994;56:217-226.
6. ^{vi} Browner BD, Jupiter JB, Levine AM, Trafton PG, eds: *Skeletal Trauma: Basic Science, Management, and Reconstruction*, ed 3. Philadelphia, PA, Saunders,.2002.
7. ^{vii} Court-Brown CM, Garg A, McQueen MM. The epidemiology of proximal humeral fractures. *Acta Orthop Scand*. 2001;72: 365-371.
8. ^{viii} Boileau P, Krishnan SG, Tinsi L, Walch G, Coste JS, Mole' D. Tuberosity malposition and migration: reasons for poor outcomes after hemiarthroplasty for displaced fractures of the proximal humerus. *J Shoulder Elbow Surg*. 2002;11:401-412.
10. ^{ix} Dai J, Chai Y, Wang C, Wen G. Meta-analysis comparing locking plate fixation with hemiarthroplasty for complex proximal humeral fractures. *European journal of orthopaedic surgery & traumatology: orthopedie traumatologie*. 2014;24(3):305-13.