

## EFFECT OF RETAINING UTERUS DURING RESECTIONING FOR RECTOSIGMOID ENDOMETRIOSIS

<sup>1</sup>Dr Paritosh Das Agrawal, <sup>2</sup>Dr Anubha Agarwal

<sup>1,2</sup>Varun Arjun Medical College and Rohilkhand Hospital, Banthra, Shahjahanpur. UP

**Article Info:** Received 07 January 2020; Accepted 03 February 2020

**DOI:** <https://doi.org/10.32553/ijmbs.v4i2.1852>

**Corresponding author:** Dr Anubha Agarwal

**Conflict of interest:** No conflict of interest.

### Abstract

**Background:** Endometriosis is a gynaecological disorder in which there is a presence of endometrial tissue in places other than the uterus wall. The study deals with the endometriosis in the rectosigmoid part, leading to several clinical features like dysmenorrhea, dyspareunia, dyschezia, etc. The surgical management is done on these patients by removing the rectosigmoid part, with or without hysterectomy.

**Objective:** The study intended to find out the effects or the impact of rectosigmoidectomy with or without hysterectomy in patients of rectosigmoid endometriosis.

**Design:** A retrospective cohort study with 97 patients.

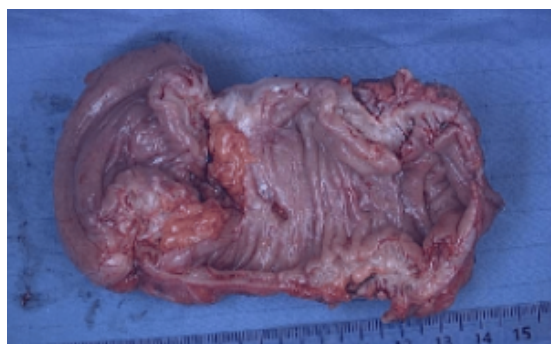**Results:** The post-surgical data and post-surgical clinical features show an insignificant difference between the Hysterectomy group and the Non-Hysterectomy group. This shows that retaining the uterus during Rectosigmoidectomy in Rectosigmoid endometriosis does not affect the postoperative complications. 16 patients had post-surgical complications with a hysterectomy and 12 patients had post-surgical complications without hysterectomy. Also, the reduction of clinical features among the two groups is almost similar. After surgery, among the patients who underwent a hysterectomy, 1 patient still had clinical features of endometriosis while 5 patients still showed clinical features of endometriosis. **Conclusion:** The study concluded that post-surgical complications are not significantly different between both the cases of anterior rectosigmoidectomy with or without hysterectomy. Also, the clinical features are reduced in both the groups who underwent hysterectomy and those who did not.

**Keywords:** endometriosis; bowel endometriosis; recto sigmoid; rectosigmoidectomy; hysterectomy

### Introduction

Endometriosis is a disorder in gynaecology that is characterized by the presence of endometrial gland tissue (stroma) apart from the uterus. One of the most aggressive forms is Pelvic endometriosis with the involvement of the bowel (Figure 1). Although it can be asymptomatic, it mostly leads to dyspareunia, dysmenorrhea, dysuria,

dyschezia, tenesmus and pain during the defecation [1]. Rectosigmoid endometriosis is a disease that is of unknown pathogenesis and origin. After many years Sampson described rectosigmoid endometriosis as an ectopic implant of the menstrual cavity that is passed through the fallopian tubes into the abdominal cavity [2].



**Figure 1: The deep endometriosis of rectosigmoid**

In recent years Benagiano and Brosens suggest that rectosigmoid endometriosis may likely occur due to the deprivation of the hormones, such as estrogen, in the neonatal period that is expressed by many newborn girls in a

retrograde fashion [2]. Burney and Giudice put forward the Celomic theory which stated that embryonic cells persist in ectopic locations. These embryonic cells are from the Mullerian ducts. Endometriotic lesions are build-up as the

embryonic cells grow in puberty by stimulation of estrogens [3].

Nyholt *et al.* stated that rectosigmoid endometriosis is a hormone-dependent genetic disease. The meta-analysis was conducted which concluded that there are 5 loci that can be considered as the risk factors in the development of endometriosis. These 5 loci are together involved in the biochemical pathway of sex steroids [4].

The imaging still leaves most of the disease undiagnosed as there is no accurate serum marker. Ultrasound provides good specificity (89%) and sensitivity (83%) in the diagnosis of endometriomas. The sensitivity and specificity in diagnosing deep infiltrating endometriosis, rectovaginal septum, bladder, and uterosacral ligaments range between 53-93% [5].

In recent times high-resolution magnetic resonance imaging has been a breakthrough with the contrast of bladder, vaginal, and rectal. Laparoscopy is the gold standard in diagnosing endometriosis and also in removing all the disease parts, it should be performed only by experienced surgeons. Medical management has been a center piece in the treatment of rectosigmoid endometriosis. In the olden times, gestrinone and danazol have been used, they are used only when there is an absolute absence of side effects and when the other treatments have been proved to be ineffective. Progestagens have been proved to be efficient, whereas for the long-term use agonist of gonadotropin-releasing hormone is not reliable. The extent of the lesions is controlled by oral progestin tablets on a long-term basis [6,7]. Combined oral contraceptives provide pain relief initially but there is a lack of clinical evidence in support of the treatment of endometriosis. In August 2018, a drug ulipristal was not approved in treating myomas as it resulted in severe risk factors like endometrial hyperplasia and carcinoma. Also, from the United States Food and Drug Administration (USFDA), there are reports of damage to the hepatic tissues [8]. Elagolix NR is an oral gonadotropin-releasing hormone antagonist that shows very few side effects and also arrests the disease progression. It is effective in reducing endometriosis-associated pain when used for 12 months at a daily dose of 200 mg. This drug has got approval for use as a hormonal backup treatment [9].

### **Surgical management**

A study was conducted in the university hospital of Aarhus on the referral unit of tertiary endometriosis. The medical records of the patients diagnosed with rectosigmoid endometriosis were seen in 2009 January and a follow was done for more than six months. The results of the MRI, demographic data and time of the second surgery were recorded. The data of 238 patients with the diagnosis of rectosigmoid endometriosis were included, of the 78 patients, who underwent primary surgery, 27 members underwent a second surgery, and 135 members were under conservative treatment. In a referral centre about more than

half of the patients were undergoing conservative treatment, more than 80% of the patients avoided surgery [10].

The best treatment for moderate to severe endometriosis is the excision of the tissue surgically. The surgical excision can be done either by excision of only the endometriosis by preserving the reproductive tract or by excision of the endometriosis followed by hysterectomy. The hysterectomy is especially effective for the pain in the pelvic region where endometriosis is eliminated in the uterus muscle. Preservation of the ovaries is considered using hysterectomy if most of the endometriosis is excised [11].

Usually, endometriosis is diagnosed between the age of 12 and 80 years with a mean of 28 years old. The disease is caused due to multi-factors, mainly attributable to environmental and genetic factors. The hormonal exposure of estrogen is one of the significant biochemical etiology of endometriosis. It is found that caucasians are more likely to have endometriosis as compared to Africans and Asians. Increased prevalence is found among the taller females with lower BMI. The risk factors that are identified in causing endometriosis are early menarche, nulliparity, prolonged menses while the protecting factors identified are menopausal status, multiparity, pregnancy and lactation [12, 13, 14].

### **Effect of endometriotic tissue even after surgical removal**

The most common cause for the recurrence of endometriosis is the incomplete excision of the endometriosis and also depends on the type of hysterectomy; it affects the recurrence of the symptoms mainly by the extent to which the lesion is excised. The drainage of ovarian cyst is associated with a high recurrence of reformation of the cyst within a span of three to six of surgery. There is a recurrence of pelvic pain in 3.5% of the patients who are on hormone replacement therapy. A high recurrence rate of 62% is seen in advanced stages of endometriosis where the ovaries are preserved, it shows a 6 fold risk of recurrence of pain and an 8 fold risk of reoperating the patient. The decision is made by taking into consideration the patient's age and also the impact of early menopause. The surgery should always aim in eradicating the lesion to decrease the risk of recurrence [15].

### **Materials and Methods**

The present study was conducted in a tertiary hospital from June 2019 to September 2021. The study design is a retrospective cohort. The patients were selected from the inpatient department of Gynaecology in that tertiary care hospital. The inclusion criteria of the patients in this study were, all the patients had rectosigmoid endometriosis which is confirmed by the clinical features and Endoscopic Ultrasound (EUS) via the rectal route. Another criterion of patient's inclusion were that the patients who had rectal wall infiltration, more than 1 lesion of any size in the rectosigmoid part, unresponsive hormonal treatment for more than 6 months, were only considered for this study. The patients were excluded from participating in the study for the

following criteria, namely, menopausal women, history of past intestinal surgeries or any pelvic surgeries, existing or history of the case of malignancies, non-cooperative or irregular for follow-up. Applying the above criteria, the study considered 97 such patients.

The selected patients were given surgical resection of the rectosigmoid region through an anterior abdominal approach (rectosigmoidectomy). 52 patients were given surgical resection along with hysterectomy and 45 patients without hysterectomy (Non-Hysterectomy group), who chose to preserve their fertility. Hence, the selected patients (97 in number) were divided into 2 groups, namely, the "Hysterectomy" group and the "Non-Hysterectomy" group, which have 52 patients and 45 patients, respectively. The patients who were considered for the surgery study were examined pre-operatively.

## Surgical Management

The said institute is a tertiary care unit and so, it has a standard surgical team that has carried out the Rectosigmoidectomy with or without hysterectomy according to the patient's demand. The standard pre-operative protocol including the routine tests has been done. The bowel was prepared 24 hours before the surgery, with 100 mL of lactulose. A rectal enema was performed before starting the surgery. Antibiotic cefazolin 2 g was given prophylactically 2 hours before the surgery to all the patients. The primary surgical procedure comprised of resection of the rectosigmoid region with complete removal of the endometriotic lesion. The secondary procedure was optional (that is, hysterectomy or removal of the uterus) and was carried out in the mentioned patients. The flow of management in this study is summarized below (Figure 2). Thus, in 82 patients hysterectomy was done or the uterus was removed while in 68 patients, the hysterectomy was not done and these 68 patients have retained their fertility.

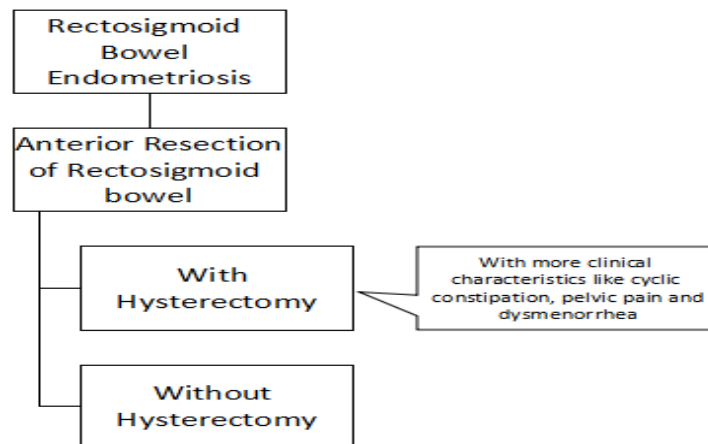


Figure 2: The flow of management followed in this study

## Post-Surgery and analysis

Post-surgical methods included recording the patient's complications in each group (namely, "hysterectomy" group and "non-hysterectomy" group). The length of stays is also recorded. At the time of discharge, each patient is analyzed for the outcomes (complete resolution of pain or reduced pain) of both the treatment procedures (anterior rectosigmoidectomy with hysterectomy and without hysterectomy).

## Results

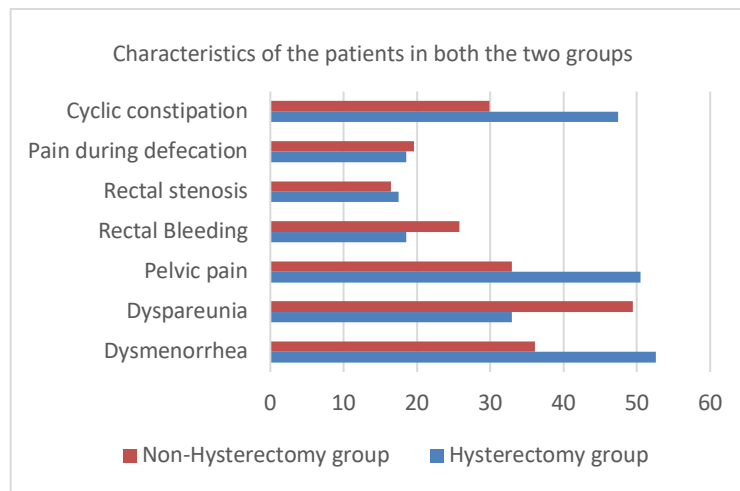
### Patient's characteristics

The study involved 97 patients, whose rectosigmoidectomy was carried out. The patients were divided into two groups, Hysterectomy group (who underwent Anterior Rectosigmoidectomy with hysterectomy) and Non-Hysterectomy group (who underwent Anterior Rectosigmoidectomy without hysterectomy). The mean age of the patients in Hysterectomy group and Non-

Hysterectomy group is 32.4±3.5 years old and 29.6±2.3 years old respectively. The BMI is also similar in both the groups, 24.5±2.1 Kg/m<sup>2</sup> and 23.1±3.6 Kg/m<sup>2</sup> for Hysterectomy and Non Hysterectomy groups, respectively. The study showed that 53.6% of the total patients had hysterectomy with anterior rectosigmoidectomy while 46.39% of the patients chose to preserve the uterus. While admission to the hospital, 52.57% of the patients from Hysterectomy group and 36.08% of the patients from Non-Hysterectomy group are reported to have dysmenorrhea. Pelvic pain is reported in 50.51% of the patients in Hysterectomy group and 32.98% of the patients in Non-Hysterectomy patients. During admission, 47.42% of the Hysterectomy group patients had cyclic constipation while 29.89% of the Non-Hysterectomy patients had the same. Other clinical features that were found in the patient during admission were dyspareunia, rectal bleeding, rectal stenosis, pain during the defecation. The total number of findings are summarised in the table below (Table 1 and Figure 3).

**Table 1: Characteristics of the patients in both the two groups**

| Parameter                                       | Hysterectomy group | %     | Non-Hysterectomy group | %     |
|---|--------------------|-------|------------------------|-------|
| Total Number                                    | 52                 | 53.6  | 45                     | 46.39 |
| Age   | 32.4±3.5           |       | 29.6±2.3               |       |
| BMI (Kg/m <sup>2</sup> )                        | 24.5±2.1           |       | 23.1±3.6               |       |
| Clinical Features of Rectosigmoid Endometriosis |                    |       |                        |       |
| Dysmenorrhea                                    | 51                 | 52.57 | 35                     | 36.08 |
| Dyspareunia                                     | 32                 | 32.98 | 48                     | 49.48 |
| Pelvic pain                                     | 49                 | 50.51 | 32                     | 32.98 |
| Rectal Bleeding                                 | 18                 | 18.55 | 25                     | 25.77 |
| Rectal stenosis                                 | 17                 | 17.52 | 16                     | 16.49 |
| Pain during defecation                          | 18                 | 18.55 | 19                     | 19.58 |
| Cyclic constipation                             | 46                 | 47.42 | 29                     | 29.89 |

**Figure 3: Characteristics of the patients in both the two groups**

The post-surgical data shows an insignificant difference between Hysterectomy group and Non-Hysterectomy group. This shows that retaining the uterus during Rectosigmoidectomy in Rectosigmoid endometriosis does not affect the postoperative complications (Table 2). Also, the reduction of clinical features among the two groups is almost similar (Table 3).

**Table 2: Post-surgical complications among the two groups**

| Post-surgical complications                                  | Hysterectomy group | Non-Hysterectomy Group |
|--|--------------------|------------------------|
| Temporary catheterization                                    | 2                  | 1                      |
| Anastomotic leaks  | 0                  | 0                      |
| Ileus  | 0                  | 0                      |
| Gastric complications leading to readmission after discharge | 6                  | 5                      |
| Pancreatitis   | 1                  | 0                      |
| Fistula  | 0                  | 0                      |
| Infections   | 0                  | 0                      |
| Postoperative constipation                                   | 7                  | 6                      |

**Table 3: Post-surgical clinical features among the two groups**

| Clinical Features      | Hysterectomy Group | Non-Hysterectomy Group |
|------------------------|--------------------|------------------------|
| Dysmenorrhea           | 0                  | 1                      |
| Dyspareunia            | 1                  | 1                      |
| Pelvic pain            | 0                  | 2                      |
| Rectal Bleeding        | 0                  | 0                      |
| Rectal stenosis        | 0                  | 0                      |
| Pain during defecation | 0                  | 0                      |
| Cyclic constipation    | 0                  | 1                      |

## Discussion

### Effects of endometriosis:

The main clinical features associated with endometriosis are severe pain, infertility, and other persisting symptoms [16]. These are involved in a wide range including dyschezia, dysmenorrhea, dyspareunia but endometriosis can even decrease the life span of a patient, causes complications in surgical procedures, abnormalities in the anatomy due to adhesions, dysfunction of bowel and bladder, but if it is an ovarian endometrioma it can even lead to the development of cancer [17]. It is found from several papers which state that infertile females have a 7 to 8 times higher probability to have endometriosis than fertile females. Though several mechanisms are put forward to explain this finding. But none can be satisfactory in supporting the exact mechanism explaining infertility in females diagnosed with endometriosis is not reached [18]. Chronic pelvic pain is the most common association with endometriosis as 71% to 87% of the females diagnosed with endometriosis suffer from chronic pelvic pain [19]. This disease negatively affects the overall quality of life of the patients in terms of the patient's physical health, emotional status, social and sexual life as well as other lifestyles of the patients. Endometriosis also affects the daily schedule of the patient and in long term, negatively affects family planning [20]. Compared to healthy women, females diagnosed with endometriosis show an increase in stress levels, affects the quality of sleep and decreased physical activity. Females diagnosed with endometriosis exhibit symptoms like constipation or problems in the digestion caused due to the inflammatory irritation of the gastrointestinal system but not due to the nodules of the endometrium affecting the rectum [21]. Endometriosis was considered a benign condition primarily but subsequent study findings in the researchers conducted showed an increase in the associated risk of ovarian cancer in the females diagnosed with endometriosis [22].

### Bowel complications after rectosigmoidectomy:

A retrospective study was conducted in a tertiary hospital among 413 women of reproductive age diagnosed with bowel endometriosis, who underwent rectosigmoidectomy from 2005 to 2018 without any previous history of bowel surgery or any history of malignancies. The data was collected from the records of the patients included the length of the segment that is resected, the distance of the lesion from the anus and also the complications associated with endometriosis. A survey was conducted using a questionnaire before the surgery and at 2nd, 6th and 12th month periods after the surgery which provided information on the urinary and intestinal function. The conclusion of the study showed an increase in the bleeding from the rectum and stool thinning, after 2 months of the surgery. The study also recorded a gradual decrease of other symptoms over a while [23].

The postoperative symptoms like rectal bleeding and other urinary symptoms were seen in females where the lesion is

close to the anal verge, it is not associated with the length of the segment that is resected. There was no correlation seen between the stooling frequency and the length of the segment resected [24]. At 6 months after the surgery, the patients showed a decrease in the frequency of stooling where the resection is done closer to the anal verge when compared to the ones with no change or increase in the frequency of stooling [25].

### Retention of endometriotic tissue after surgical removal:

For the treatment of superficial peritoneal endometriosis excision and ablation type of laparoscopic techniques are effective equally. Laparoscopic cystectomy is superior in treating ovarian endometriosis to coagulation and drainage [26]. The pain associated with endometriosis is reduced by excision of deep rectovaginal endometriosis that is in association with or without rectal invasion.

For dome type of endometriosis laparoscopic partial bladder cystectomy is more advisable than in lesions with vesicles. Hysterectomy done by preserving the ovaries shows an increase in the risk of pain recurrence. Recurrence of pain is seen with hormonal treatment despite bilateral oophorectomy [27].

In countries such as the United States, many hysterectomies are performed for a primary diagnosis of endometriosis and for nearly 12% of the patients with endometriosis, it is likely to go for a hysterectomy. Anecdotal clinical observation states that the patients achieve satisfactory relief from pain after hysterectomy, but the patients should be informed priorly of the chance of pain recurrence [28].

Namnoum conducted a study on the outcome of hysterectomy with and without preserving the ovaries. The study concluded that there is a 6 fold rise in recurrent pain and an 8 fold risk in re-operating the patient [29]. Dyspareunia and chronic pelvic pain are the most common symptoms of recurrent endometriosis. Rectal and vaginal bleeding, and also rectal and low back pain are also the symptoms of recurrent endometriosis. Severe dyspareunia and pain may indicate lesions that are deep infiltrating [30]. The lesions of the endometrium are the main cause for the majority of the recurrent symptoms of endometriosis, where the ovaries and the uterus is removed but some lesions of the endometrium are left behind deep inside. This was the standard practice for many years as endometrium would undergo atrophy in the absence of estrogen, but it was not definite that endometriosis would undergo complete regression in the absence of estrogen [15]. The most common sites where the lesions recur are the small and large bowel after oophorectomy and hysterectomy. The most effective strategy in reducing endometriosis is by removing estrogen production [31]. The data that is collected suggests that the hysterectomy done by preserving the ovarian tissues shows an increase in the recurrence of the symptoms and an increase in the risk of re-operation. Shakiba *et al.* (2008) reported in their study that hysterectomy done by preserving both the ovaries shows an increase in the risk of re-operating

the patient by 2.44 times regardless of the patient's age [32]. Further studies found that for women in the age group of 30-39 years, oophorectomy did not change the re-operating strategy. Taking both studies into consideration, the females who undergo hysterectomy with bilateral oophorectomy show less incidence of further surgery. However, conserving the ovaries is the best option in some women mainly under the age group of 40 years diagnosed with advanced endometriosis [32].

### Conclusion

The study explored the surgical management of rectosigmoid endometriosis by conducting anterior resection of the rectosigmoid part with or without retaining the uterus. It concluded that post-surgical complications are not significantly different between both the cases of anterior rectosigmoidectomy with or without hysterectomy (Refer to Table 2). Also, the clinical features are reduced in both the groups who underwent hysterectomy and those who did not (Refer to Table 3). However, hysterectomy has been shown to reduce the pain of endometriosis completely. The study suggests formulating a rationale of the management plan in each case of rectosigmoid endometriosis.

### References

1. Daraï E, Marpeau O, Thomassin I, et al. Fertility after laparoscopic colorectal resection for endometriosis: preliminary results. *Fertil Steril.* 2005;84(4):945–950.
2. Brosens I, Benagiano G: Is neonatal uterine bleeding involved in the pathogenesis of endometriosis as a source of stem cells? *Fertil Steril.* 2013; 100(3): 622–3.
3. Burney RO, Giudice LC: Pathogenesis and pathophysiology of endometriosis. *Fertil Steril.* 2012; 98(3): 511–9.
4. Sapkota Y, Steinhorsdottir V, Morris AP, et al.: Meta-analysis identifies five novel loci associated with endometriosis highlighting key genes involved in hormone metabolism. *Nat Commun.* 2017; 8: 15539.
5. Guerriero S, Mais V, Ajossa S, et al.: The role of endovaginal ultrasound in differentiating endometriomas from other ovarian cysts. *Clin Exp Obstet Gynecol.* 1995; 22(1): 20–2.
6. Johnson NP, Hummelshoj L; World Endometriosis Society Montpellier Consortium: Consensus on current management of endometriosis. *Hum Reprod.* 2013; 28(6): 1552–68.
7. Bedaiwy MA, Allaire C, Alfaraj S: Long-term medical management of endometriosis with dienogest and with a gonadotropin-releasing hormone agonist and add-back hormone therapy. *Fertil Steril.* 2017; 107(3): 537–48
8. Ignatov T, Eggemann H, Dan Costa S, et al.: Endometrial cancer after ulipristal acetate for uterine fibroma. *Eur J Obstet Gynecol Reprod Biol.* 2017; 219: 134.
9. Lessey BA, Diamond MP, Agarwal S, et al.: Long-term effect of elagolix on the endometrium: Results from two phase 3 extension studies in women with endometriosis-associated pain. *Fertil Steril.* 2017; 108(3): e45.
10. Egekvist, A. G., Marinovskij, E., Forman, A., Kesmodel, U. S., Riiskjaer, M., & Seyer-Hansen, M. (2017). Conservative approach to rectosigmoid endometriosis: a cohort study. *Acta Obstetrica et Gynecologica Scandinavica*, 96(6), 745–750. <https://doi.org/10.1111/aogs.13094>
11. Reich H, Redan JA, Orbuch IK. Laparoscopic hysterectomy for advanced endometriosis including rectosigmoid disease. *Surg Technol Int.* 2004;13:121-36. PMID: 15744683.
12. Missmer SA, Hankinson SE, Spiegelman D, Barbieri RL, Marshall LM, Hunter DJ. Incidence of laparoscopically confirmed endometriosis by demographic, anthropometric, and lifestyle factors. *Am J Epidemiol* 2004; 160:784?
13. Nyholt DR, et al. Genome-wide association meta-analysis identifies new endometriosis risk loci. *Nat Genet.* 2012 Dec; 44(12):1355-9. doi: 10.1038/ng.2445. Epub 2012 Oct 28.
14. Pagliardini L, Gentilini D, Viganò P, Panina-Bordignon P, Busacca M, Candiani M, Di Blasio AM. An Italian association study and meta-analysis with previous GWAS confirm WNT4, CDKN2BAS and FN1 as the first identified susceptibility loci for endometriosis. *J Med Genet.* 2013 Jan; 50(1):43-6. doi: 10.1136/jmedgenet-2012-101257.
15. Rizk, B., Fischer, A. S., Lotfy, H. A., Turki, R., Zahed, H. A., Malik, R., Holliday, C. P., Glass, A., Fishel, H., Soliman, M. Y., & Herrera, D. (2014). Recurrence of endometriosis after hysterectomy. *Facts, views & vision in ObGyn*, 6(4), 219–227.
16. Macer ML, Taylor HS. Endometriosis and infertility: a review of the pathogenesis and treatment of endometriosis-associated infertility. *Obstet Gynecol Clin North Am.* 2012 Dec; 39(4):535-49.
17. Parasar P, Ozcan P, Terry KL. Endometriosis: Epidemiology, Diagnosis and Clinical Management. *Curr Obstet Gynecol Rep.* 2017 Mar;6(1):34-41.
18. Bulletti C, Coccia ME, Battistoni S, Borini A. Endometriosis and infertility. *J Assist Reprod Genet.* 2010 Aug;27(8):441-7.
19. Bloski T, Pierson R. Endometriosis and Chronic Pelvic Pain: Unraveling the Mystery Behind this Complex Condition. *Nurs Womens Health.* 2008 Oct;12(5):382-95.
20. Marinho MCP, Magalhaes TF, Fernandes LFC, Augusto KL, Brilhante AVM, Bezerra LRPS. Quality of Life in Women with Endometriosis: An Integrative Review. *J Womens Health (Larchmt).* 2018 Mar;27(3):399-408.
21. Roman H, Bridoux V, Tuech JJ, Marpeau L, da Costa C, Savoye G, Puscasiu L. Bowel dysfunction before and after surgery for endometriosis. *Am J Obstet Gynecol.* 2013 Dec;209(6):524-30.

22. Králíčková M, Laganà AS, Ghezzi F, Vetvicka V. Endometriosis and risk of ovarian cancer: what do we know? *Arch Gynecol Obstet.* 2020 Jan;301(1):1-10.
23. Bassi, M. A., Andres, M. P., Bassi, C. M., Neto, J. S., Kho, R. M., & Abrão, M. S. (2020). Postoperative Bowel Symptoms Improve over Time after Rectosigmoidectomy for Endometriosis. *Journal of Minimally Invasive Gynecology*, 27(6), 1316–1323. <https://doi.org/10.1016/j.jmig.2019.10.009>
24. Chen, X., Zhang, H., Li, N., & Feng, J. (2016). Pathological changes of interstitial cells of Cajal and ganglion cells in the segment of resected bowel in Hirschsprung's disease. *Pediatric Surgery International*, 32(11), 1019–1024. <https://doi.org/10.1007/s00383-016-3961-7>
25. Roman H, Bubenheim M, Huet E, et al. Conservative surgery versus colorectal resection in deep endometriosis infiltrating the rectum: a randomized trial. *Hum Reprod.* 2018; 33:47–57.
26. Wee-Stekly, W.-W., Kew, C. C. Y., & Chern, B. S. M. (2015). Endometriosis: A review of the diagnosis and pain management. *Gynecology and Minimally Invasive Therapy*, 4(4), 106–109. <https://doi.org/10.1016/j.gmit.2015.06.005>
27. Golfier, F., & Sabra, M. (2007). Prise en charge chirurgicale de l'endométriose. *Journal de Gynécologie Obstétrique et Biologie de La Reproduction*, 36(2), 162–172. <https://doi.org/10.1016/j.jgyn.2006.12.005>
28. Rizk B, Abdalla H. *Fast Facts: Endometriosis.* (2nd ed.) Oxford: Health Press, 2003
29. Namnoum AB, Hickman TN, Goodman SB et al. Incidence of symptom recurrence after hysterectomy for endometriosis. *Fertil Steril.* 1995;64:898-902
30. Clayton RD, Hawe JA, Love JC et al. Recurrent pain after hysterectomy and bilateral salpingo-oophorectomy for endometriosis: evaluation of laparoscopic excision of residual endometriosis. *BJOG.* 1999; 106:74-4.
31. ACOG Practice Bulletin. Practice bulletin no. 114: management of endometriosis. *Obstet. Gynecol.* 2010; 116: 223-36.
32. Yildiz, S., Kaya, C., Alay, I., Cengiz, H., Ekin, M., & Yasar, L. (2020). The pain symptoms and mass recurrence rates after ovarian cystectomy or uni/bilateral oophorectomy procedures in patients over 40 years old with endometriosis. *Ginekologia Polska*, 91(6), 295–300. <https://doi.org/10.5603/gp.2020.0053>.