|| ISSN(online): 2589-8698 || ISSN(print): 2589-868X ||
International Journal of Medical and Biomedical Studies
Available Online at www.ijmbs.info
NLM (National Library of Medicine ID: 101738825)
Index Copernicus Value 2021: 70.61
Case Report Volume 6, Issue 11; November: 2022; Page No. 09-10

Marfan's Syndrome

Dr Mohd Tajuddin[1], Dr Basavaraj R Puranik[2], Dr B. Prahalad[3]

[1]Final Year Post Graduate Department of General Medicine Shadan Institute of Medical Sciences, Peeramcheru, Hyderabad, Telangana State, India
[2]Professor and HOD of Department of General Medicine Shadan Institute of Medical Sciences, Peeramcheru, Hyderabad, Telangana State, India
[3]Professor Department of General Medicine Shadan Institute of Medical Sciences, Peeramcheru, Hyderabad, Telangana State, India

Article Info: Received 08 October 2022; Accepted 05 November 2022
DOI: https://doi.org/10.32553/ijmbs.v6i11.2618
Corresponding author: Mohd Tajuddin
Conflict of interest: No conflict of interest.

Abstract
Marfan's syndrome is a congenital anomaly characterized by disorders of the connective tissue manifested principally by changes in skeleton, ocular and cardiovascular manifestation.

Introduction

Marfan's syndrome is named after Antoine Marfan, the French pediatrician who first described the condition in 1896. It is a most common inherited connective tissue disorder [1,2].

Case report

A 17 years old male patient name Riyaz Ali resident of peeramcheru Hyderabad, came to medical op with complaints of pain in the left side of chest and fever Since 3-4 months. Patient had an episode of high fever with chills & rigors followed by chest pain. Pain was sudden in onset, dragging in nature, strong in intensity, continuous, radiating to left side of neck, temporal side of skull upwards and inframammary region involving left shoulder and elbow. Patient also gives history of paroxysmal nocturnal dyspnea, shortness of breath on brisk walking & climbing. No history of hemoptysis, cough or hospitalization for any lung infection. In past medical history, patient had two syncopal attacks within a year following extreme chest pain. no history of HTN, DM, TB, Jaundice. Patient was taking painkillers since 3-4 months for chest pain. No history of sudden death among family members but grandfather's brother was tall like him.

On examination: Patient was conscious, coherent and cooperative, febrile - 103 F, respiratory rate - 32/ min, blood pressure - 130/80 mmHg, pulse - irregular, 60 beats/min, his height is 190cm, weight is 45kgs, arm span is 198cms, upper segment of body is 90cm, lower segment of the body is 100cm. Patient had mild scoliosis of vertebral column. Skull is dolichocephalous, high arched palate, crowding of upper teeth, pigeon shaped chest (pectus carinatum), has ligament laxity, joint hypermobility seen in metacarpal and metatarsophalangeal joint, has long limbs, extremities (arachnodactyly) pes planus seen in feet, striae on shoulders. Wrist sign & thumb sign (+) arm span > height | Lower segment > upper segment. No Clubbing, Cyanosis, Pallor, lymphadenopathy. JVP not raised, no pedal edema, apex beat is visible. On palpation apex beat is felt on 5th intercostal space & tenderness over precordium, on auscultation mitral click, pansystolic murmur heard | lungs are clear. Lower border of lens is seen in both eyes but more prominent in left eye, Ectopia Lentis outward and temporal side. CNS: no neurological deficit.

Figure 1: Showing High Arched Palate.

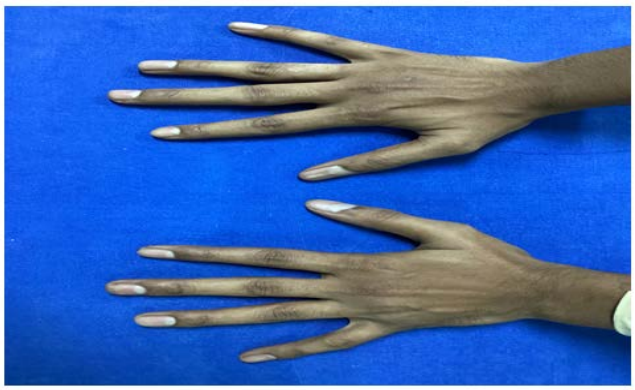

Figure 2: Showing Arachnodactyly

Discussion:

Marfan's syndrome is a congenital anomaly characterized by disorders of the connective tissue manifested principally by changes in skeleton, ocular and cardiovascular system. The diagnosis of MFS relies essentially on the fulfillment of clinical diagnostic criteria as outlined by the revised Ghent criteria[3]. Due to heterogeneous mutation in Fibrillin FBN1 gene on chromosome 15q21.1

The mutated Fibrillin FBN1 gene causes production of a protein with an abnormality amino acid sequence that disrupts the normal assembly of micro fibrils[4,5]. Fibrillin is a major component of micro fibrils found in extra cellular matrix. These fibres provide scaffolding on which tropo-elastin is deposited to form elastic fibres. Although micro fibrils are widely distributed in the body. They are particularly abundant in aorta, ligaments, ciliary zonules that support the lens; these tissues are predominantly affected. Excessive TGF beta signal has the deleterious effects on vascular smooth muscle development & integrity of ECM.

Conclusion:

Marfan's syndrome is an inherited connective tissue disorder affecting ocular, skeleton, and cardiovascular system, as the above case met Ghent criteria and all investigations are found positive in diagnosing Marfan's syndrome.

Ethical Approval: The study was approved by the institutional ethical committee.

Acknowledgment: we would like to acknowledge our HOD - department of General Medicine, Medical director, Medical Super indent, Shadan institute of medical sciences Hyderabad.

References:

1. Ramirez F, Godfrey M, LeeB, et al. Marfan syndrome and related disorders. In: Scriver CR, Beaudet AL, Sly WS, et al., editors. the metabolic Molecular Basis of inherited Disease. New York: McGraq Hill; 1995. p. 4079
2. Judge DP, Dietz HC. Marfan's syndrome. Lancet. 2005 Dec 3; 366(9501):1965-76.
3. Loeys BL, Dietz HC, Braverman AC, et al. The revised Ghent nosolgy for the Marfan syndrome. J Med Genet. 2010 jul;47(7):476-85.
4. Dietz H, Ramirez F, SakaiL. Marfan syndrome and other microfibrillar diseases. In: Harris H, Hirschhorn K, editors. Advances in human genetics. Vol.22. New York: Plenum Press; 1994. pp. 153-86.
5. Akhurst RJ. TGF beta signaling in health and disease. Nat Genet.2004 Aug; 36(8):7902.