

Characteristics of Patients with Follicular Ameloblastoma at Oral Surgery Department of Dr. Hasan Sadikin General Hospital 2019 - 2020

Yasinnurrasyad Azmabasyar Rausyanfikir¹, Agus Nurwiadh², Asri Arumsari³

¹Resident, Department of Oral and Maxillofacial Surgery, RSUP Dr. Hasan Sadikin, Faculty of Dentistry, Padjadjaran University, Bandung 40161, Indonesia

²Department of Oral and Maxillofacial Surgery, Faculty of Dentistry, Universitas Padjadjaran, Bandung 40161, Indonesia

³Department of Oral and Maxillofacial Surgery, RSUP Dr. Hasan Sadikin, Universitas Padjadjaran, Bandung 40161, Indonesia

Received: 11-08-2023 / Revised: 04-09-2023 / Accepted: 30-09-2023

DOI: <https://doi.org/10.32553/ijmbs.v7i10.2738>

Corresponding author: Yasinnurrasyad Azmabasyar Rausyanfikir

Conflict of interest: No conflict of interest.

Abstract

Introduction: Ameloblastoma is the most common odontogenic tumor. Ameloblastoma is an intermediate (borderline) tumor since it is benign but locally invasive with a high recurrence rate if the excision is incomplete. Radiologically it can be monocystic or polycystic and histopathologically shows different characteristics with the follicular as the most occurrence type.

Method: This research is a descriptive study using medical record data of patients who diagnosed with ameloblastoma. The population for this study were patients with a diagnosis of follicular type ameloblastoma from January 2019 to December 2020 at the Oral Surgery Department of Dr. Hassan Sadikin Hospital.

Result: The result shows ameloblastoma occurred in 62% of women (26 patients) and 38% of men (16 patients). The type of ameloblastoma was varies, as the follicular type was found in 24 cases (57%), followed by the plexiform type which was found in 16 cases (38%) and the mixed plexiform-follicular type was found in 2 cases (5%). The treatment shows the conservative management of ameloblastoma using the dredging method in 9 patients (21%). Radical management of these data involved marginal resection in 1 patient (2%), segmental resection in 18 patients (43%), hemimaxillectomy in 3 patients (7%), and hemimandibulectomy in 11 patients (26%)

Conclusion: ameloblastoma is more common in women than men. The follicular type is more common than plexiform or the mixed type of ameloblastoma. Based on the location of the ameloblastoma, the most common is the mandible. Radical surgery is the most common used for ameloblastoma management.

Keywords: Follicular Ameloblastoma, Oral Surgery

Introduction

Ameloblastoma is the most common odontogenic epithelial neoplasm. Nalabolu et al. in 2016 discovered that ameloblastoma occurs in 49% of cases of odontogenic tumors. Ameloblastoma is

slow growing but locally invasive, does not show any pain so it is usually found at the advanced stage, showed swelling and bone destruction.^{1,2,7}

This tumor originates from remnants of the malases epithelium, dental lamina, epithelial walls of odontogenic cysts, basal cells of the mucosal epithelium and remnants of Hertwig's fibers found in the periodontal ligament of a tooth that is growing from its enamel organ. Ameloblastoma usually occurs as a central lesion in the jawbone that destroys slowly and enlarges from the ruling spongiosa towards the cortex. About 17% of ameloblastomas are associated with impacted teeth or dentigerous cysts.⁸

The radiographic appearance of ameloblastoma is a radiolucent appearance, either unilocular or multilocular (soap bubble). Root resorption is rare but is usually seen in rapidly growing lesions. Figure 1 shows a unilocular lesion around the impacted third molar. These lesions have a tendency to grow in size with buccal and lingual expansion and root resorption might be seen. There is a change in the position of the teeth and mandibular canal.^{11,12}

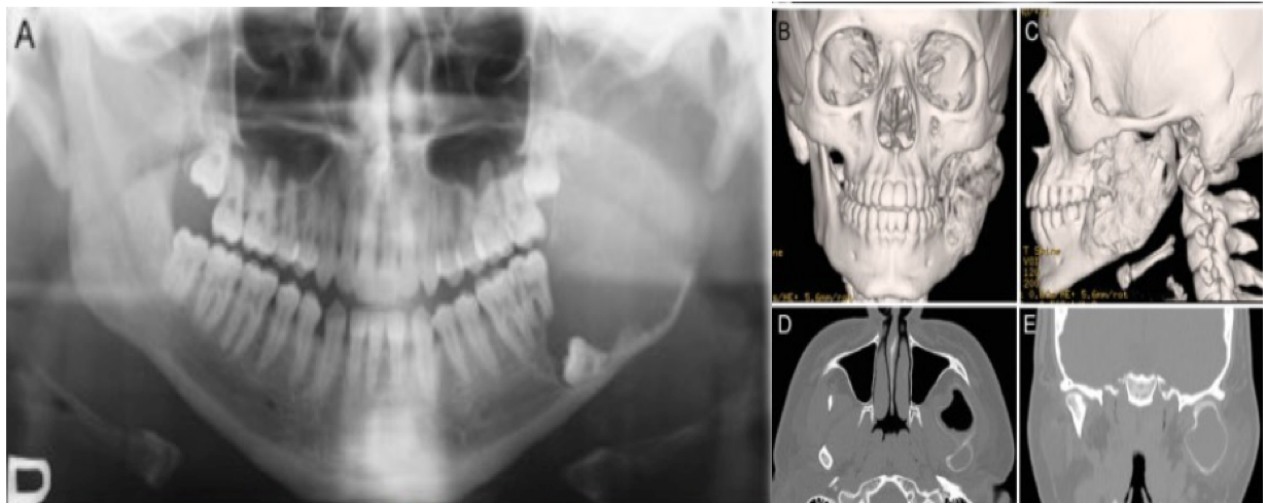


Figure 1: Unicyclic Ameloblastoma; **A.** Unicyclic panoramic view of ameloblastoma on left mandibular ramus and condyle; **B and C.** 3D CT scan picture of unicyclic ameloblastoma in left mandibular ramus and condyle involving buccal, lingual, anterior and posterior expansion; **D.** Coronal CT image of invasion of the condylar head and condylar expansion¹²

Multicyclic ameloblastoma is more easily recognized by the characteristic appearance of a multilocular lesion and is described as a soap bubble appearance accompanied by buccal and lingual cortical expansion, resorption of tooth roots and radiolucent appearance of unerupted teeth.

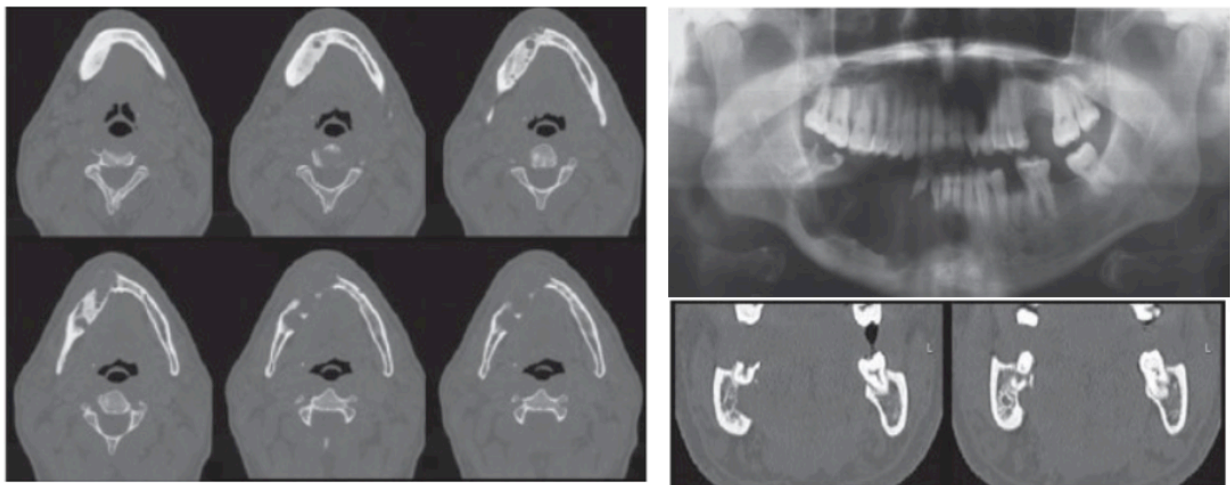


Figure 2: Multicyclic Ameloblastoma

Method

This research is a descriptive study using medical record data of patients diagnosed with ameloblastoma. The sample in this study were patients diagnosed radiologically and histopathologically as follicular type ameloblastoma at Hasan Sadikin General Hospital in the period January 2019 - December 2020. This study was conducted using a total sample. The variables studied included age, sex, clinical diagnosis, histopathological diagnosis, and management.

Data collection was carried out using the total sampling method using the medical records of follicular type ameloblastoma patients treated by KSM Oral Surgery at Hasan Sadikin General Hospital for the period of January 2019 to December 2020. The collected data was processed computerized to turn data into information.

The data processing steps starts from editing; checking the correctness of the required data. Coding; changing data in the form of sentences or letters into numeric data or numbers. Data entry; entering data as the results of examination and measurement of research subjects have been coded, the data is entered into a computer program.

And cleaning; when all data from the patient has been entered, it needs to be rechecked to see the possibility of code errors, incompleteness, and so on, then corrections are made. The data was obtained through medical records from January 2019 to December 2020.

Numerical data will be expressed in terms of mean standard deviation. Categorical data will be expressed in proportions and percentages (%). Data analysis if needed can use SPSS.

Results

The collecting data result on ameloblastoma patient of Oral Surgery Department of Dr. Hasan Sadikin Hospital in the period of January 2019 to December 2020 showed 42 patients who received treatment.

Figure 3 shows that there were 42 patients diagnosed with Ameloblastoma at RSHS, divided into 16 males (38%) and 26 females (62%). In Figure 4 the data shows that the age range of 21-30 is the most common age range, with 12 patients in total (29%), and in the age range 0-10 years as the minimum age that can be affected by ameloblastoma is 1 patient (2%). The incidence of ameloblastoma in Indonesia occurs at an average age of 21-30 years.

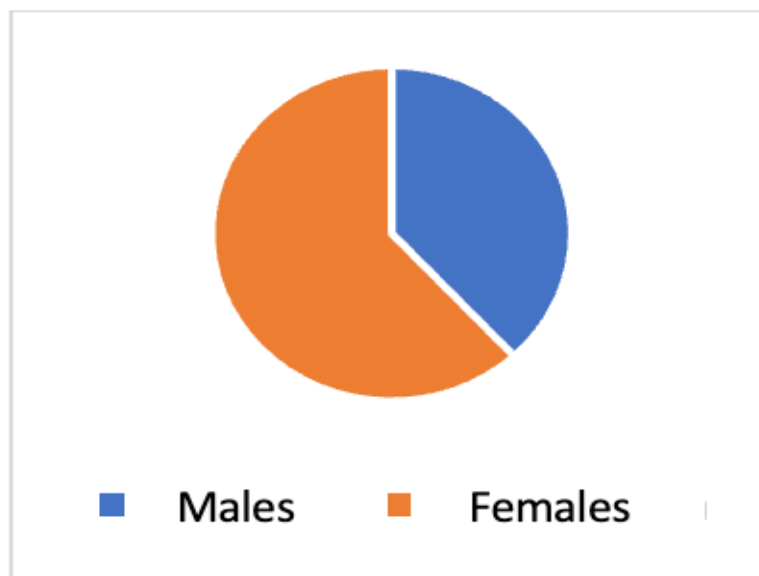


Figure 3: Gender Distribution of Ameloblastoma

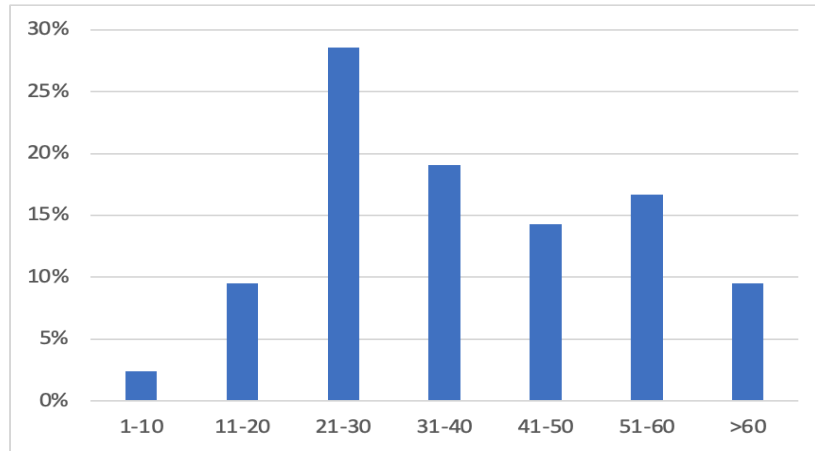


Figure 4: Age Distribution of Ameloblastoma

Based on the location of the tumor, the results showed ameloblastoma occurred on the maxilla in 4 patients (10%), and occurred on the mandible in 38 patients (90%) (Figure 5).

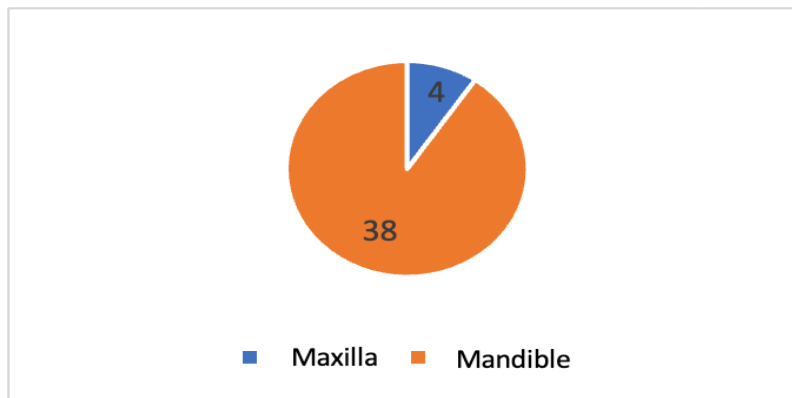


Figure 5: the result of ameloblastoma predilection

Figure 6 shows the conservative management of ameloblastoma using the dredging method in 9 patients (21%). Radical management of these data involved marginal resection in 1 patient (2%), segmental resection in 18 patients (43%), hemimaxillectomy in 3 patients (7%), and hemimandibulectomy in 11 patients (26%).

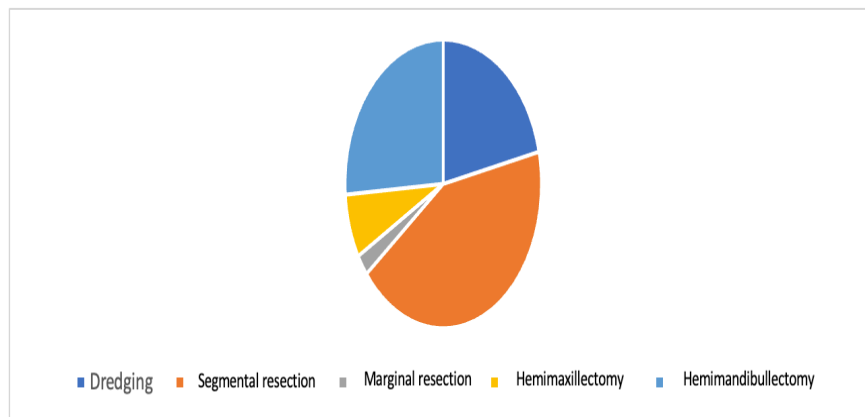


Figure 6: Ameloblastoma management distribution

Discussion

The characteristics of ameloblastoma based on radiographic examination and anatomic pathology are very diverse, and analysis is needed to determine the characteristics that often occur in patients at KSM Oral Surgery RSHS. Based on the results of data collection, it can be seen that the incidence of ameloblastoma that occurred and received treatment at RSHS in the period January 2019 to December 2020 totaled 42 patients, with an average age of 37 years. Based on research conducted by Ruslin on the average age distribution of ameloblastoma patients in the community in Makassar, Indonesia, which is 39.7 years, this reinforces the theory that the highest incidence of ameloblastoma is in the third to fourth decades.⁴

The distribution by examination of anatomical pathology resulted that cases that often occurred in patients treated at RSHS during the period January 2019 - December 2020 were the most frequent cases of follicular ameloblastoma, namely 24 cases, followed by 16 cases of plexiform ameloblastoma. Another case that occurred was mixed type ameloblastoma which was a combination of plexiform and follicular ameloblastoma occurring in 2 cases.

Treatment for the treatment of ameloblastoma can be divided into conservative treatment and radical treatment. According to Muller, the action that can be chosen by the majority is radical treatment where if using this treatment, the recurrence rate is only 15% compared to conservative treatment which is more than 50%. Based on the data obtained at RSHS, the action that was more often performed was segmental resection, namely 18 cases, followed by hemimandibulectomy in 11 cases, and hemimaxillectomy in 3 cases. Conservative measures performed in RSHS such as dredging were 9. Radical surgery is more often used in RSHS because it aims to reduce the recurrence rate of cases of ameloblastoma that occur, whereas conservative measures are indicated in pediatric and adolescent patients, as well as adult patients with unilocular ameloblastoma.

Conclusion

Ameloblastoma was most common in women than men. There were several variations of the type and three main histopathological types. Follicular form is the most common type, followed by the plexiform and the mixed plexiform-follicular type. Based on the location of ameloblastoma, the most commonly found were. Radical surgery is the most used treatment for ameloblastoma cases such as segmental resection, total mandibulectomy, and total maxillectomy.

References

1. Nalabolu GRK, Mohiddin A, Hiremath SKS, et al. *Epidemiological Study of Odontogenic Tumours : An Institutional Experience*. Journal of Infection and Public Health.2017; 10 : 324 - 330
2. Andersson L, Khanberg KE, Pogrel MA. *Oral and Maxillofacial Surgery*. 2010. ed-1; 32:629-728. United Kingdom : Blackwell Publishing
3. Fonseca RJ, Carlson ER, Ness GM. *Oral and Maxillofacial Surgery*. 2018. ed-3 (2) : 301.481. Missouri : Elsevier.
4. Ruslin, M. Hendra FN. Vojdani A, et al. *The Epidemiology, Treatment, and Complication of Ameloblastoma in East Indonesia : 6 years retrospective surgery*. Med Oral Patol Oral Cir Bucal. 2018. Jan 1;23 (1):e54-8.
5. Lumerman HS, Bowe RB. 2012. *Atlas of Oral and Maxillofacial Histopathology*. ed-2; 2: 21-60. Philadelphia : Walters Kluwer Health.
6. Aramanadka C, Kamath AT, Kudva A. *Recurrent Ameloblastoma: A Surgical Challenge*. Hindawi : Case Reports in Dentistry. 2018 : 1-6
7. Mc Clary AC. West RB. Pollack JR. et al. *Ameloblastoma: a clinical review and trends in management*. Eur Arch Otorhinolaryngol. 2016 : 1-13
8. Effiom OA, Ogundana OM, Akinshipo AO, Akintoye SO. *Ameloblastoma : current etiopathological concepts and management*. Oral Diseases (2018) 24, 307–316

9. Masthan KMK, Anitha N, Krupaa J, et al. *Ameloblastoma*. J Pharm Bioallied Sci. 2015 Apr; 7(Suppl 1): S167–S170
10. Jeddy N, Jeyapradha T, Ananthalakshmi R, Jeeva S, Saikrishna P, Lakshmi P. *The molecular and genetic aspects in the pathogenesis and treatment of ameloblastoma*. J Dr NTR Univ Health Sci. 2013;2:157–61.
11. Koong B. 2017. *Atlas of Oral and Maxillofacial Radiology*. ed-1; 10: 153-178 United Kingdom : John Wiley & Sons Ltd.
12. Sasaki R, Watanabe Y, Ando T, et al. *Two Stage Enucleation and Deflation of a Large Unicystic Ameloblastoma with Mural Invasion in Mandible*. *Craniofacial Trauma Reconstruction*. 2014;7:139–142
13. Barbosa GL, Oliveira ML, Almeida SM, et al. *Computed Tomography Imaging Features of Multicystic Granular Cell Ameloblastoma : A Case Report*. *Stomatos*, Vol. 20, 39, Jul-Dec. 2014
14. Beena VT, Choudhary K, Heera R, et al. *Peripheral Ameloblastoma : A Case Report and Review Literature*. Hindawi Publishing Corporation. 2012;1 -4
15. Neville DW, Damm DD, Allen CM, Chi AC. 2016. *Oral and Maxillofacial Pathology*. ed-4; 15 : 653-668. Missouri : Elsevier
16. Sadat S, Ahmed M. “*Dredging Method*”- *A Conservative Surgical Approach for the treatment of Ameloblastoma Jaw*. Journal of Bangladesh College of Physicians and Surgeons. Vol 29. No.2. 2011
17. Au SW, Li KY, Choi WS, et al. *Risk factors for recurrence of ameloblastoma : a long-term follow up retrospective study*. *Int. J. Oral Maxillofac. Surg.* 2019; 7 : 1-7
18. Wright JM, Tekkesin MS. *Odontogenic tumors: where are we in 2017*. *J Istanbul Univ Fac Dent* 2017;51:10–30.
19. Chichua N, Pai S, Gigineishvili E, Sharashenidze M. *Management of Ameloblastoma : Desirable Treatment Approach*. *Caucasus Journal of Health Science and Public Health*. Vol 1. 2016
20. Gunawardane S R, Attygalla A M. *The Dredging Method: an Alternative Technique for Conservative Management of Ameloblastoma. A Case Report*. *Sri Lanka Dental Journal* 2017; 47(02) 23-27. 2017
21. Malhiero P., Feio L., Costa H., *Unicystic Plexiform Ameloblastoma: Case Report*. *Revista De Saude Amato Lusitano* 2013; 32, p. 54
22. Santis GD, Cordeiro PG, Chiarini L. 2019. *Atlas of Mandibular and Maxillary Reconstruction with The Fibula Flap : A step-by-step approach*. ed-1;2 : 3-12. Switzerland : Springer