

ACUTE CALCULOUS CHOLECYSTITIS IN A YOUNG FEMALE PATIENT: A UNIQUE CASE

Ni Nengah Tuti Arianthi¹, Christina Permata Shalim¹, Made Suma Wirawan²

¹General Practitioner, Wangaya Regional General Hospital, Denpasar, Bali, Indonesia

²Internist, Department of Internal Medicine, Wangaya Regional General Hospital, Denpasar, Bali, Indonesia

Article Info: Received 03 July 2019; Accepted 04 August. 2019

DOI: <https://doi.org/10.32553/ijmbs.v3i8.430>

Address for Correspondence: Christina Permata Shalim, General Practitioner, Wangaya Regional General Hospital, Denpasar, Bali, Indonesia

Conflict of interest: No conflict of interest.

Abstract

Acute cholecystitis needs to be rapidly diagnosed and treated correctly. The classic patient characteristics were obese, increasing age, and being female. In a few cases, cholecystitis can occur in an atypical patient, such as in young age. Here, we report a 25-year-old obese female patient that came with right upper abdominal pain which was associated with nausea and vomiting. From imaging studies, we found that she had distended gallbladder with multiple stones. Open cholecystectomy was done and patient did well postoperatively. Acute cholecystitis had to be suspected in all age, especially in patient with another risk factor like obesity in our case.

Keywords: acute cholecystitis, gallstone, cholecystectomy

Introduction:

Despite wide availability of diagnostic tool such as abdominal ultrasound and wide range of empirical antibiotics, acute cholecystitis still represents the second source of complicated intra-abdominal infection (18.5%).¹ Timely diagnosis was important because cholecystitis actually has an excellent prognosis if diagnosed and treated correctly. Patient characteristic and clinical manifestation are usually typical to suspect someone had an acute cholecystitis. The classic patient characteristics were obese, increasing age, and being female.^{2,3} But in a few cases, cholecystitis also occurred in an atypical patient. Here, we present a case of acute cholecystitis that occurred in young female patient.

Case Report

A 25-year-old, female patient presented in the emergency department with 1 week history of right upper abdominal pain which was associated with nausea and vomiting. The pain started as an epigastric pain then radiated to her right upper quadrant and aggravated in the last 4 days. There was an increased in pain intensity with deep respiration. She also had fever over the last 3 days. There was history of dark urine, but no pale stools.

She had experienced similar symptom in the last year and already diagnosed with cholelithiasis but refused the surgery treatment. Besides that, her past medical history was unremarkable with no surgical history.

On presentation, the patient looked obese, with body weight of 90 kg and height of 158 cm (BMI 31.25 kg/m²). She was febrile with a temperature of 37.9°C and slightly tachycardic to 100 bpm. There was scleral icterus and jaundice on her skin. Abdominal examination showed tenderness to palpation on the right upper quadrant with positive Murphy's sign.

Complete blood count showed leukocytosis with a white blood cell count of $11.80 \times 10^3/\mu\text{L}$. Hemoglobin was 14.1 g/dL, hematocrit 42.6%, and platelet count $340 \times 10^3/\mu\text{L}$. There was elevated liver enzyme with AST 433 U/L and ALT 428 U/L. Her direct and total bilirubin was also elevated with direct bilirubin 5,5 mg/dL and total bilirubin 5,8 mg/dL. Abdominal ultrasound was performed and showed a distended gallbladder with multiple stones (Figure 1).

A CT scan of the abdomen showed hepatomegaly and multiple cholelithiasis with cholecystitis, without dilated intrahepatic bile duct or extrahepatic bile duct. From the CT scan it appeared the gallstones did not obstruct the common bile duct, but only the cystic duct (Figure 2).

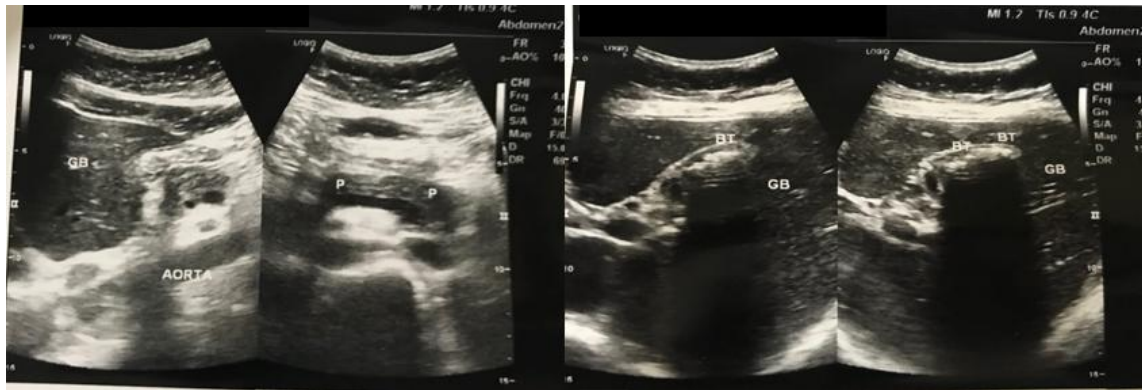

Figure 1: Abdominal Ultrasound

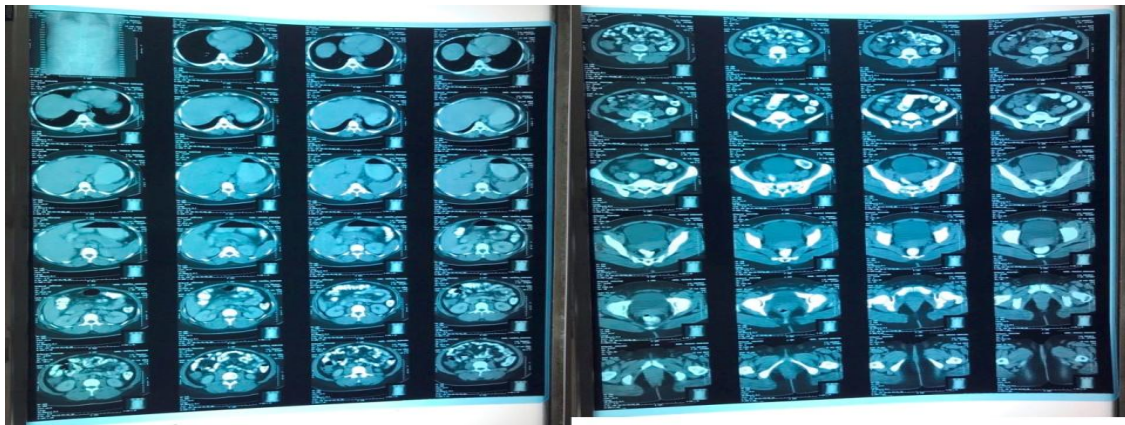


Figure 2: Abdominal CT Scan

From these findings, a diagnosis of acute cholecystitis with multiple cholelithiasis was being made and the decision was to consult the surgeon to do cholecystectomy. Meanwhile, the patient was treated with empiric antibiotic ceftriaxone intravenously, gallstones dissolution agent ursodeoxycholic acid (UDCA) and symptomatic therapy including ketorolac, paracetamol, and omeprazole.

Open cholecystectomy was performed, and the findings of multiple cholelithiasis was confirmed. The measurements of the gallbladder were 6.3 cm long, and 3.2 cm at its widest point and 2 cm at its narrowest point. The largest gallstones were 6 mm in diameter (Figure 3).

The gallstones were then analyzed to know the stone composition. The results were the gallstones composed of cholesterol, carbonate, iron, and bile pigment. The gallstones analysis results did not describe the cholesterol content of gallstones, but based on the composition and the gallstones appearance we assumed the gallstones to be mixed stones.



Figure 3: Patient's gallbladder and gallstones after cholecystectomy

The patient did well postoperatively. She was discharged on the third day after the surgery.

Discussion

Some classic risk factors that was known for cholelithiasis was obesity, increasing age, and being female. Our patient is female and obese, but just 25 years old at the time. The frequency of cholelithiasis increases with age. In one of the prevalence study that conducted in China, the cholelithiasis prevalence in female aged 50 years and under was just 6,13%, whereas that in patients above 50 years old was high, at 33%. Thus, it still is considered unusual for young patient to have cholelithiasis.²

Symptomatic stones usually produced recurrent episodes of right upper quadrant (RUQ) or epigastric pain. Approximately 60-70% of patients reported having experienced prior attacks that resolved spontaneously. Patient may experience intense pain in the RUQ of

the abdomen that steadily increases for approximately 30 min to several hours. The pain may radiate to the interscapular area, right scapula, or shoulder. Often, attacks precipitated by eating fatty meal and frequently happen at night.^{4,5}

When patient with gallstones present with acute cholecystitis, the symptoms become more severe. Acute inflammation of the gallbladder wall usually follows obstruction of the cystic duct by a stone. Peritoneal signs such as increased pain with deep respiration may be apparent. Vomiting is relatively common and may produce signs and symptoms of dehydration. Jaundice may occur early when edematous inflammatory changes involve the bile ducts and surrounding lymph nodes.^{4,5}

From the physical examination, usually patient has low grade fever. The RUQ of the abdomen is almost always tender to palpation, with deep inspiration or cough during RUQ palpation usually produces increased pain and inspiratory arrest. This characteristic physical examination finding was known as Murphy’s sign.⁶ Murphy's sign sensitivity was 62% and specificity was 96% for acute cholecystitis diagnosis.⁷

The diagnosis is made based on this clinical features and supported by findings from relevant laboratory and imaging studies. The triad of sudden onset of RUQ pain, fever, and leukocytosis is highly suggestive of acute cholecystitis. Typically, leukocytosis in the

range of 10.000-15.000 cells/mL is found with a left shift on differential count. The serum bilirubin is usually mildly elevated and modest elevations in serum aminotransferases can be found.

Abdominal ultrasound is the preferred initial imaging technique for patients who are clinically suspected to have acute calculous cholecystitis because of its lower cost, better availability, lack of invasiveness, and high accuracy for gallbladder stones.⁸ Ultrasound also does not expose the patient to radiation. Right upper quadrant ultrasound has >95% sensitivity and specificity to detect gallbladder stone.⁹ However, its sensitivity and specificity for diagnosing acute cholecystitis was relatively low. In the study by Borzellino et al., distention of the gallbladder, wall edema, and pericholecystitis fluid collection were used as the criteria for the presence of acute calculous cholecystitis. The presence of at least one these three criteria on AUS resulted in sensitivity of 83.7% and specificity of just 47.7%.¹⁰

Tokyo Guidelines 2013 (TG13) diagnostic criteria and severity grading of acute cholecystitis was widely used. In 2018 this criteria had been reviewed and still proofed to be useful in clinical practice, therefore it adapted as TG18/TG13 criteria without any modification (Table 1). This criteria combine clinical sign, laboratory, and imaging findings for diagnosis of acute cholecystitis and differentiate the diagnosis as suspected and definite. Based on this diagnostic criteria, our patient fulfilled the criteria for definite diagnosis of acute cholecystitis.¹¹

Table 1: TG18/TG13 diagnostic criteria for acute cholecystitis¹¹

TG18/TG13 diagnostic criteria for acute cholecystitis	
	Local signs of inflammation etc. Murphy’s sign. (2) RUQ mass/pain/tenderness
B.	Systemic signs of inflammation etc. Fever, elevated CRP, (3) elevated WBC count
C.	Imaging findings Imaging findings characteristic of acute cholecystitis
Suspected diagnosis: one item in A + one item in B	
Definite diagnosis: one item in A + one item in B + C	

After the diagnosis of acute cholecystitis is being made, the next step was to consider the appropriate treatment for the patient. In acute calculous cholecystitis, gallstones dissolution agent such as ursodeoxycholic acid (UDCA) was usually given in the patients waiting for elective cholecystectomy. However, current guidelines do not recommend the

use of this oral dissolution agent, because some trials showed this as ineffective.^{8,12} Complete dissolution with UDCA can be achieved in just 50% of patients within 6 months to 2 years at a dose of 8-10 mg/kg/day.⁵

Of the 75% of patients with acute cholecystitis who undergo remission of symptoms without surgery intervention, around 25% of them will experience a recurrence of cholecystitis within 1 year. Therefore, it is thought that acute cholecystitis is best treated by early surgery whenever possible. However, a period of in-hospital stabilization may be required before cholecystectomy. Nonsteroidal anti-inflammatory drugs (NSAIDs) are usually used for analgesia because they may produce less spasm of the sphincter of Oddi than drugs such as morphine. Intravenous antibiotic is usually indicated.⁵ Antibiotic therapy is usually guided by the most frequently isolated microbes. Organisms most often isolated in biliary infections are the gram-negative aerobes, *Escherichia coli* (31-44%) and *Klebsiella pneumonia* (9-22%).^{8,13} Guidelines from World Society of Emergency Surgery make a recommendation for antimicrobial regimens for community acquired acute calculous cholecystitis, which are beta-lactam/beta-lactamase inhibitor combinations, cephalosporins, carbapenem, fluoroquinolone, and glycolcylcline.⁸

The optimal timing of surgical therapy in patients with acute cholecystitis depends on stabilization of the patient. Urgent cholecystectomy is considered in most patients in whom complication such as empyema, emphysematous cholecystitis, or perforation is suspected or confirmed.⁵ One of the largest cohort with data on 87,108 cholecystectomies showed that the optimal timing for surgery was within the first 2 days after hospital admission with a significantly lower risk for adverse event. Meanwhile, surgery on admission day, despite had a significantly better outcome than in those being operated 5 days or more after admission, had a higher frequency of adverse events compared to surgery performed 1 or 2 days after admission. This finding might be caused by the fact that some patient not being in the optimal condition when surgery was performed on admission day because lack of time required for resuscitation and stabilization.¹⁴

After cholecystectomy, ideally a gallstone was analyzed to know their material composition. Detection of chemical composition of gallstone is important to identify their mechanism of formation.¹⁵

There is a few variety of gallstone classification, but traditional classification that commonly used divided gallstones into 3 types according to cholesterol content: cholesterol stone (cholesterol $\geq 70\%$), pigment stone (cholesterol content $\leq 30\%$) and mixed stone (30% \leq cholesterol content $\leq 70\%$). Pigment stone can be subdivided into black pigment gallstones (cholesterol content 10-15%) and brown pigment gallstones (5-10%).^{15,16}

Cholesterol and calcium bilirubinate are the main chemical compound in gallstones and their precipitation in bile is induced by multiple etiological factors. Supersaturation of cholesterol in bile is important for cholesterol stone formation. Calcium bilirubinate precipitation occurs due to defective bilirubin conjugation and present as the main chemical compound in pig-ment gallstones. Calcium carbonate, calcium phosphate and calcium fatty also can be found in gallstones as minor compounds.¹⁵

Based on the appearance, cholesterol stones appeared brownish yellow, amber, grey, jade green or black and their shape were spherical or polyhedron. They were of different sizes, soft, and the surfaces were smooth and glossy or rough. Pigment stones were amorphous, brittle, granules that were black, charcoal grey or grayish brown in color. The appearance of mixed stones depends on their components.¹⁶

On our case, the result of gallstone analysis showed gallstones composed of cholesterol, carbonate, iron, and bile pigment. The gallstones analysis result did not describe the cholesterol content of gallstones, but based on the composition and the gallstones appearance we assumed the gallstones to be mixed stones. This finding is in line with previous research that showed in female patient age 20-29 years the most common gallstones type was mixed stones.¹⁶

Conclusions

Cholecystitis can occurred in an atypical patient. Acute cholecystitis had to be suspected in all age, especially in patient with another risk factor like obesity in our case so it can be rapidly diagnosed and treated correctly.

References

1. Sartelli M, Abu-Zidan FM, Catena F, Griffiths EA, Di Saverio S, Coimbra R, et al. Global validation of the WSES Sepsis Severity Score for patients with complicated intra-abdominal infections: a prospective multicentre study (WISS Study). *World J Emerg Surg.*

- 2015;10:61.
2. Zhu L, Aili A, Zhang C, Saiding A, Abudureyimu K. Prevalence of and risk factors for gallstones in Uighur and Han Chinese. *World J Gastroenterol*. 2014 Oct 28;20(40):14942–9.
 3. Jones MW, O'Rourke MC. *Acute Cholecystitis*. StatPearls Publishing; 2019.
 4. Njeze GE. Gallstones. *Niger J Surg Off Publ Niger Surg Res Soc*. 2013 Jul;19(2):49–55.
 5. Jameson JL, Kasper DL, Longo DL (Dan L, Fauci AS, Hauser SL, Loscalzo J. *Harrison's principles of internal medicine*. 20th ed. McGraw-Hill Education / Medical; 2018.
 6. Katabathina VS, Zafar AM, Suri R. Clinical Presentation, Imaging, and Management of Acute Cholecystitis. *Tech Vasc Interv Radiol*. 2015 Dec 1;18(4):256–65.
 7. Jain A, Mehta N, Secko M, Schechter J, Papanagnou D, Pandya S, et al. History, Physical Examination, Laboratory Testing, and Emergency Department Ultrasonography for the Diagnosis of Acute Cholecystitis. Carpenter CR, editor. *Acad Emerg Med*. 2017 Mar 11;24(3):281–97.
 8. Ansaloni L, Pisano M, Coccolini F, Peitzmann AB, Fingerhut A, Catena F, et al. 2016 WSES guidelines on acute calculous cholecystitis. *World J Emerg Surg*. 2016 Dec 14;11(1):25.
 9. Demehri FR, Alam HB. Evidence-Based Management of Common Gallstone-Related Emergencies. *J Intensive Care Med*. 2016 Jan 15;31(1):3–13.
 10. Borzellino G, Massimiliano Motton A, Minniti F, Montemezzi S, Tomezzoli A, Genna M. Sonographic diagnosis of acute cholecystitis in patients with symptomatic gallstones. *J Clin Ultrasound*. 2016 Mar 4;44(3):152–8.
 11. Yokoe M, Hata J, Takada T, Strasberg SM, Asbun HJ, Wakabayashi G, et al. Tokyo Guidelines 2018: diagnostic criteria and severity grading of acute cholecystitis (with videos). *J Hepatobiliary Pancreat Sci*. 2018 Jan 1;25(1):41–54.
 12. Abraham S, Rivero HG, Erlikh I V, Griffith LF, Kondamudi VK. Surgical and nonsurgical management of gallstones. *Am Fam Physician*. 2014 May 15;89(10):795–802.
 13. Gomi H, Solomkin JS, Schlossberg D, Okamoto K, Takada T, Strasberg SM, et al. Tokyo Guidelines 2018: antimicrobial therapy for acute cholangitis and cholecystitis. *J Hepatobiliary Pancreat Sci*. 2018 Jan 1;25(1):3–16.
 14. Blohm M, Österberg J, Sandblom G, Lundell L, Hedberg M, Enochsson L. The Sooner, the Better? The Importance of Optimal Timing of Cholecystectomy in Acute Cholecystitis: Data from the National Swedish Registry for Gallstone Surgery, GallRiks. *J Gastrointest Surg*. 2017;21(1):33–40.
 15. Weerakoon H, Navaratne A, Ranasinghe S, Sivakanesan R, Galketiya KB, Rosairo S. Chemical characterization of gallstones: an approach to explore the aetiopathogenesis of gallstone disease in Sri Lanka. *PLoS One*. 2015;10(4):e0121537.
 16. Qiao T, Ma R, Luo X, Yang L, Luo Z, Zheng P. The systematic classification of gallbladder stones. *PLoS One*. 2013;8(10):e74887.