

AN AUDIT OF LUNG CARCINOMAS AT A TERTIARY REFERRAL CENTRE

Dr. Anshita Dubey¹, Dr. Meenal Hastak², Dr. Bijal Kulkarni², Dr. Nevitha Athikari², Dr. Rajesh Mistry³

¹Tutor, Department of Pathology, Pacific Institute of Medical Sciences, Udaipur.

²Consultant, Department of Histopathology, KDAH, Mumbai.

³Consultant, Department of Surgical Oncology, KDAH, Mumbai.

Article Info: Received 11 December 2019; Accepted 07 January, 2020

DOI: <https://doi.org/10.32553/ijmbs.v4i1.862>

Corresponding author: Dr. Anshita Dubey

Conflict of interest: No conflict of interest.

Abstract

A generic diagnosis of 'small cell or non-small cell carcinoma' was sufficient in the past when there was no clinical demand for sub classification as it had no impact on therapy. Patients with advanced stage non-small cell lung carcinoma who received chemotherapy were typically treated with a 'platinum doublet' of cisplatin plus gemcitabine irrespective of histological subtype. At present, in contrast, sub classification of non-small cell lung carcinoma has significant treatment implications, especially for advanced stage tumors for which chemotherapy or targeted therapy is being considered. Consequently, pathologists are asked to subtype the tumor. The demand for sub typing is driven by oncologists, who now have several new targeted therapies, the efficacy of which varies by histological subtype.

In view of demand of sub typing of lung carcinomas as well as the guidelines given by WHO 2015 classification which emphasises the importance of a separate classification for biopsies and cytology on one side and the resection specimen on the other, we have taken up this study.

Keywords: Lung carcinoma, classification, core biopsies, immunohistochemistry

Introduction

Lung cancer is the second most common cancer in males and females and the leading cause of cancer death in both sexes world-wide.(1) It is also the commonest cancer in men in India accounting for 11.3% of all new cancers and also is the most common cause of cancer death (13.7%).(2)

In today's era of advanced diagnostics and theranostics, less invasive procedures are more in demand to reduce the patients' risks associated with the procedure. But with these advances, the size of the diagnostic tissue reduces which leads to diagnostic limitations. Hence, a need of doing immunohistochemistry arises specially when the tumor morphology is not clear on H and E stained slides in case of poorly differentiated carcinomas. Although morphology on H and E stain remains the gold standard for subclassifying the carcinomas even on core biopsies, but in cases of poorly differentiated carcinomas, immunohistochemistry remains the sole basis of classification. (3) The role of special staining and IHC was emphasised in WHO 2004 classification of tumours of lung, pleura, thymus and heart. (4) In 2011 The International Association for the study of Lung Cancer/ American thoracic Society/ European Respiratory Society proposed a new classification of lung carcinomas for biopsy and cytology specimen. Here again, they emphasised on utility

of molecular test and use of IHC throughout the classification.(5)

Material and Methods:

This observational study was conducted at the histopathology department of Kokilaben Dhirubhai Ambani Hospital, Mumbai. Both biopsy and resection specimens of cases reported as primary lung carcinomas were included in the study. A total of 264 cases were studied which were received in the department in a duration of 4 years. Fixation of specimen was done in 10% buffered formalin and paraffin embedded tissue sections were stained with routine haematoxylin and eosin. These sections were examined microscopically for subtyping and grading of carcinomas and immunohistochemical markers were done which were specific for typing of carcinomas: TTF 1 and Napsin A for adenocarcinoma, p40 and p63 for squamous cell carcinoma and synaptophysin and chromogranin for small cell carcinoma. Prevalence of various types of carcinomas were studied and correlation of biopsy and resection specimen were done wherever possible. We have also evaluated the use of Immunohistochemistry in subclassification of lung carcinomas especially in core biopsies. The third aspect is trying to subclassify lung carcinomas on core biopsies and correlating the diagnosis with the resection specimens wherever possible.

Results and Discussion:

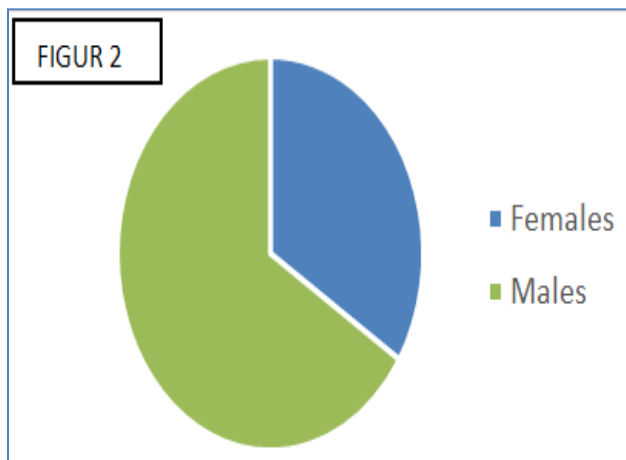
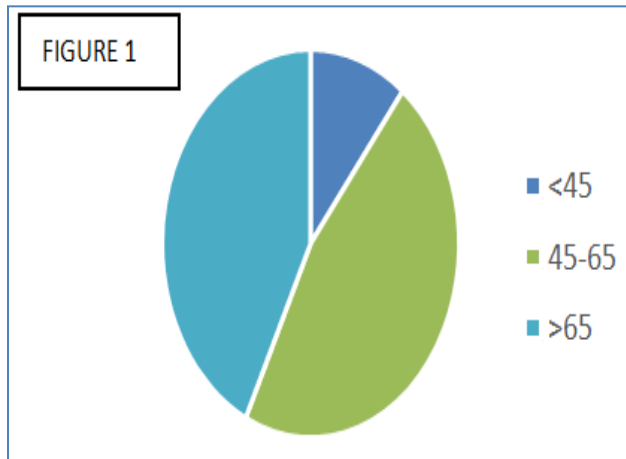


Figure 1 and 2: show age and sex distribution of primary lung carcinomas studied in 264 cases. Out of 264 cases, 28(11%) patients were below 4 years of age; 123(46%) were in between 45-65 years of age and 113(43%) cases were above 65 years of age. The mean age of lung carcinoma patients in our study 62.1 years.

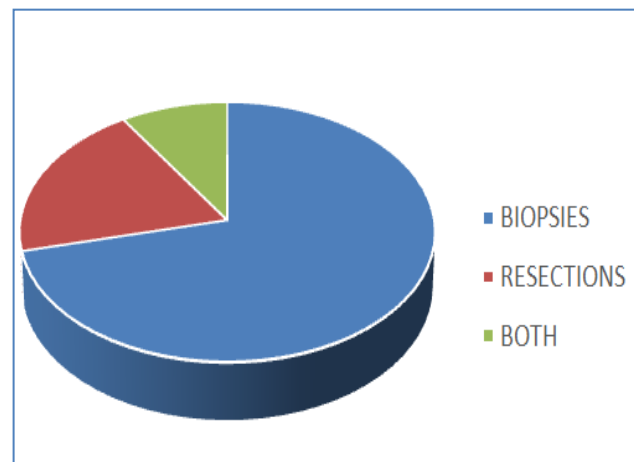


Figure 3: Types of Specimen

In 264 cases we received, there were 188 (71%) biopsies, 52 (20%) resections and in 24 (9%) cases biopsies were received followed by resection.

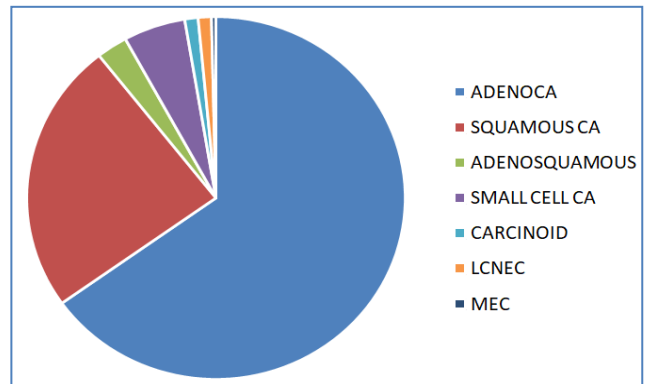


Figure 4: Subcategorization of all carcinomas

In 264 cases, the most common type of lung carcinoma was adenocarcinoma- 172(66%) cases followed by squamous carcinoma which were 64 (25%) cases, small cell carcinoma 14 (5%), adenosquamous cases were 7 (2%), both carcinoid and large cell neuroendocrine carcinoma 3(1.5%) cases each and 1(0.5%) case of mucoepidermoid.

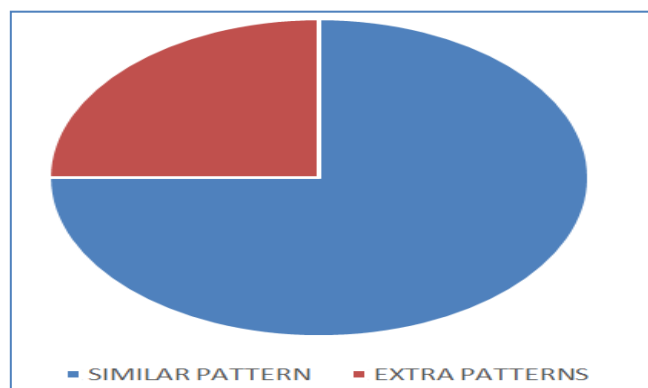


Figure 5: Morphological correlation between biopsies and resection specimen

When we correlated the diagnosis and morphological patterns seen in core biopsies and resection specimens, the sub classification remained the same in all the specimens. However, in the 24 resection specimens, we found extra patterns in 6 cases i.e 25% of the cases compared to their biopsies.

Table 1:

S. No.	Subtyping on biopsy	Subtyping on resection
1.	Adenocarcinoma; acinar pattern	Adenosquamous carcinoma
2.	Adenocarcinoma; papillary pattern	Adenocarcinoma with papillary & micropapillary pattern
3.	Adenocarcinoma; acinar pattern	Adenocarcinoma with acinar and micropapillary patterns
4.	Adenocarcinoma; papillary pattern	Adenocarcinoma with papillary, acinar and solid patterns.
5.	Adenocarcinoma; lepidic pattern	Adenocarcinoma with lepidic and micropapillary pattern
6.	Adenocarcinoma solid pattern	Adenocarcinoma with solid and acinar pattern

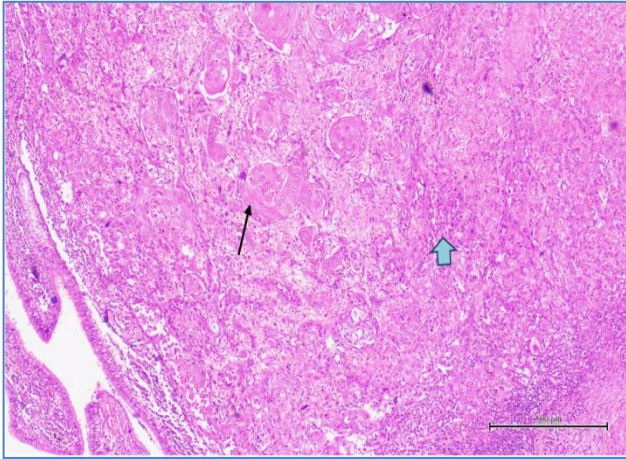


Figure 6: Adenosquamous carcinoma: H and E stained section showing both adeno (blue arrow) and squamous (black arrow) component (10X)

All the cases reported as adenocarcinoma on biopsy showed a few more patterns in resection specimens which are important to show their prognosis. Lepidic and acinar are considered as good prognostic patterns whereas micropapillary and solid are considered as poor prognostic patterns. But one case which was a moderately differentiated adenocarcinoma on biopsy turned out to be adenosquamous on resection. No IHC was done on the biopsy as it was not a poorly differentiated carcinoma as a result the squamous component was missed.

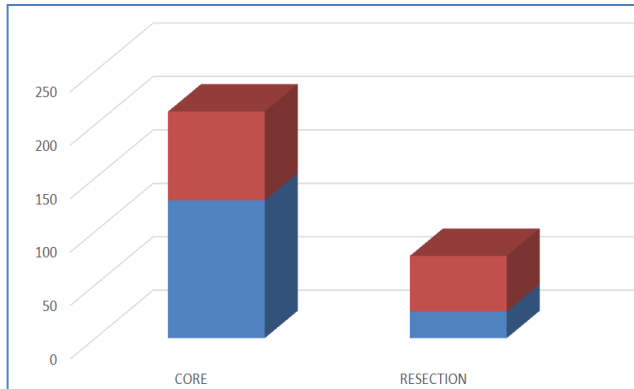


Figure 7: CASES WHICH REQUIRED IHC FOR SUBTYPING

In 212 biopsies, IHC was done on 129 (61%) cases and in 77 resections IHC was required in 25(32%) cases.

Conclusion:

Adenocarcinomas were found to be the most common subtype in our study with a common prevalence in the elderly age group. An adequate approach to core biopsies should be established. This includes proper recording of the fixation time and judiciously dividing the tissue received into two blocks so as to save tissue for the lung panel by immunohistochemistry. The H and E stained core should be looked at meticulously for exact subtyping of carcinomas. Judicious utilization of tissue should be carried out especially in core biopsies while using multiplex IHC panels.

With continuous advances, the diagnosis of lung carcinoma currently is possible with a small bore needle core biopsy. But smaller tissue increases the diagnostic challenge which can be solved by immunohistochemistry. A definite diagnosis on core has become necessary since patient specific treatment is now possible depending upon the type and subtypes of carcinoma. These parameters help clinicians to frame the treatment plan and predict the prognosis of individual patients. As pathologists, our aim should be to tailor down our diagnosis to as precise as possible with the help of IHC wherever required and also to save adequate amount of tissue for molecular tests if and when they are required.

Bibliography:

1. Key Statistics for Lung Cancer [Internet]. [cited 2018 Jun 13]; Available from: <https://www.cancer.org/cancer/non-small-cell-lung-cancer/about/key-statistics.html>
2. Behera D. SC17.03 Lung Cancer in India: Challenges and Perspectives. *J Thorac Oncol* 2017;12(1):S114–5.
3. Mukhopadhyay S. Utility of small biopsies for diagnosis of lung nodules: doing more with less. *Mod Pathol* 2012;25(S1):S43–57.
4. Beasley MB, Brambilla E, Travis WD. The 2004 World Health Organization classification of lung tumors. *Semin Roentgenol* 2005;40(2):90–7.
5. Tang Y, He Z, Zhu Q, Qiao G. The 2011 IASLC/ATS/ERS pulmonary adenocarcinoma classification: a landmark in personalized medicine for lung cancer management. *J Thorac Dis* 2014;6(Suppl 5):S589–96.